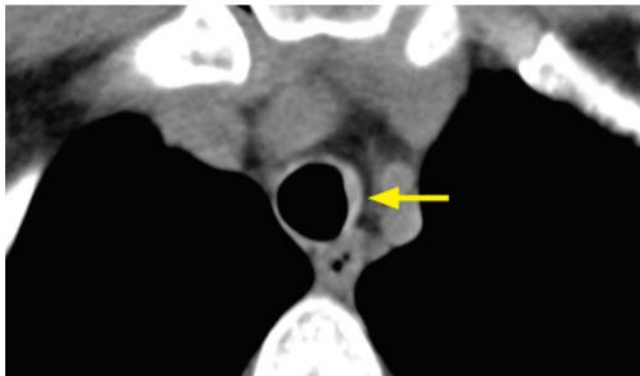
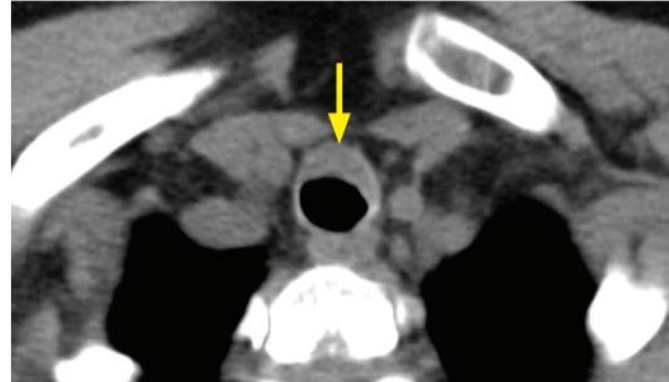
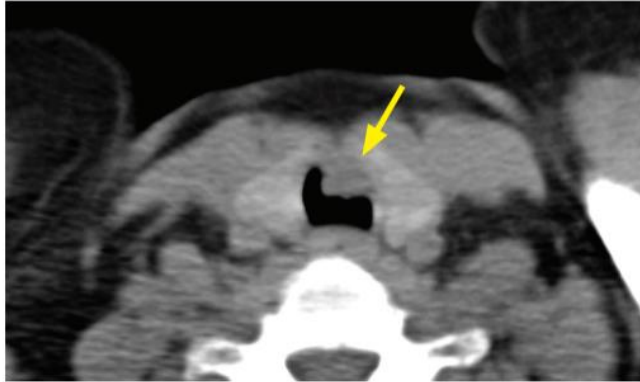


Amyloidosis



Tracheal amyloid: Axial CT images show nodular and irregular thickening of the trachea (arrows). This pattern is not specific, and the differential diagnosis would also include sarcoidosis, multifocal adenoid cystic carcinoma, and tracheal metastases.

Case courtesy Ritu R. Gill, MD, MPH, Brigham and Women's Hospital.

- Amyloidosis causes irregular narrowing of the airways due to submucosal amyloid deposition, which may be calcified. Involvement may be mass-like or segmental. Tracheal amyloidosis is very rare.
- The posterior membranous trachea is not spared.